

ONLY WITH  
**VIMAGO**  
SMALL ANIMAL CASE STUDY REVIEW

By Dr. Robert O'Brien, DVM, DACVR

## Meningioma

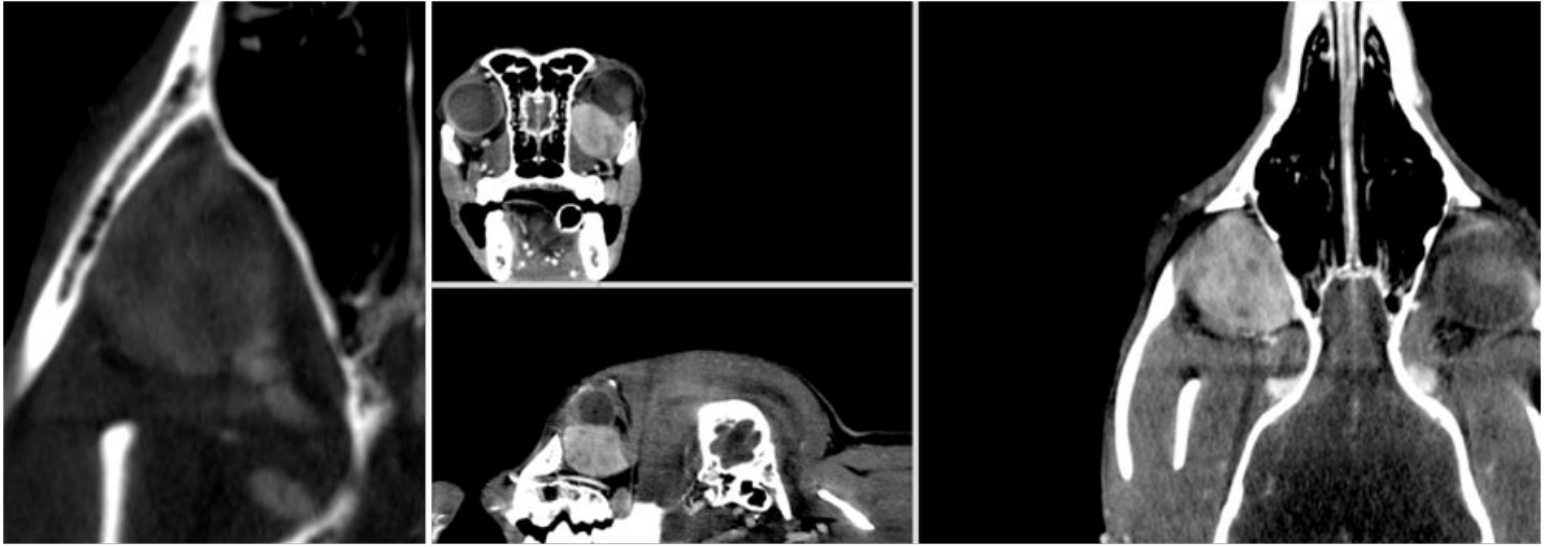


Figure 1

Figure 2

### PATIENT

9-year-old female spayed Border Collie that presented to a surgical specialty practice with a 6 month history of left sided exophthalmos.

### IMAGE PROTOCOL

A survey and post-i.v. contrast CT was performed of the head. The contrast dose was 2ml ml/lb BW of Iohexol (300mg/ml iodine) contrast media; half given as a bolus prior to image initiation and the remainder as a slow 15 sec bolus during the initial part of the 30 sec acquisition time immediately prior to image initiation.

### FINDINGS

A mass was seen ventral and caudal to the left eye (OS)(FIG 1). The mass measured 2.0 cm long 2.0 cm tall x 1.3cm wide. The mass intensely, but mildly heterogeneously enhanced indicating overall good perfusion, with small indistinctly marginated regions of ischemia or necrosis. The mass extended caudally to the rostral level of the lacrimal gland, which was not clearly seen, Dorsally the mass seemed independent of, although in contact with the globe, extraocular muscles and optic nerve. A large aberrant artery was noted entering the caudal aspect of the mass indicating neoplastic neovascularization (FIG 2). No evidence of metastasis or adenopathy was noted.

# Meningioma

## IMAGING DIAGNOSIS

Retro-bulbar mass: a. lacrimal gland adenocarcinoma (or adenoma) b. soft tissue sarcoma c. granuloma. gic.

## FINAL DIAGNOSIS

Meningioma.

## DISCUSSION POINT

This case indicates the very good contrast resolution of the Vimago™ veterinary CT scanner, indicated by the ability to resolve the contrast enhancement of the mass and excellent spatial resolution of the aberrant feeding artery. The excellent spatial resolution provided guidance for surgical resection. Whilst no obvious involvement of the mass was noted with the optic nerve and the patient had normal vision and cranial nerve reflexes, the mass was presumed to originate for the meninges surrounding the optic nerve. Approximately 3% of meningiomas are associated with the optic nerve. ***The Vimago™ HD CT has excellent spatial resolution and provides very good contrast enhancement with injected iodinated nonionic contrast medium.***